

PATIENT PRESENTING CLINICAL SIGNS

Kepler Laporta
History: 12.5 ER acute respiratory distress, 650mls chylous effusion
Medication: Lasix 3.125 BID

SPECIES ECHOCARDIOGRAPHIC FINDINGS

Feline 2D, M-mode, and Doppler study.

BREED There is moderate left atrial dilation. Left auricular function is depressed, though no spontaneous contrast or thrombi are visualized in the auricle. The mitral valve is normal. Left ventricular wall thickness is normal. There is mild left ventricular dilation. Left ventricular systolic function is normal. The aorta and aortic valve are normal. Right atrial and right ventricular dimensions are normal. The tricuspid valve is normal. The pulmonary artery and pulmonic valve are normal. No pericardial effusion or cardiac masses are seen.

DSH

SEX

FS

AGE

8 years

WEIGHT

9.1 lbs

LA - 19.0 mm
LA/Ao - 2.23
IVSd - 4.1 mm
LVPWd - 4.1 mm
LVIDd - 21.8 mm
LVIDs - 12.5 mm
FS - 42.6%
LVOT - 1.24 m/s
RVOT - 0.96 m/s

INTERPRETED BY ASSESSMENT/RECOMMENDATIONS

Keith Blass, DVM,
MS, DACVIM

This examination demonstrates moderate dilation of Kepler's left atrium and mild dilation of his left ventricle, with differentials for these findings including a restrictive cardiomyopathy (RCM), cardiac thyrotoxicosis, or a combination of the two. Given the presence of moderate left atrial dilation, it comes as no surprise that Kepler appears to have experienced an episode of congestive heart failure (CHF). In addition to recurrent CHF, Kepler is at risk for the development of thromboembolic disease and arrhythmia formation, therefore, careful monitoring for clinical signs associated with these conditions is recommended.

IMAGING PERFORMED BY

Rebekah Jakum, CVT
ARDMS/RVT

A T4 level is recommended.

HOSPITAL NAME

Maple Hills VH

Continued use of furosemide (1-2 mg/kg BID) is warranted based on this exam, as is therapy with enalapril (1.25 mg BID) and clopidogrel (18.75 mg SID).

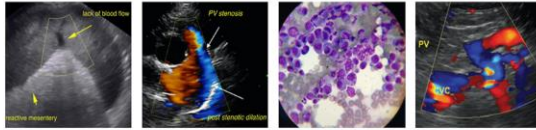
Recheck radiographs and a renal/electrolyte profile are recommended in 1 week. A recheck echocardiogram is recommended in ~6 months.

REFERRING VET

Dr. Banzhof

DATE

12.16.2021



PATIENT

Kepler Laporta

SPECIES

Feline

BREED

DSH

SEX

FS

AGE

8 years

WEIGHT

9.1 lbs

INTERPRETED BY

Keith Blass, DVM,
MS, DACVIM

IMAGING PERFORMED BY

Rebekah Jakum, CVT
ARDMS/RVT

HOSPITAL NAME

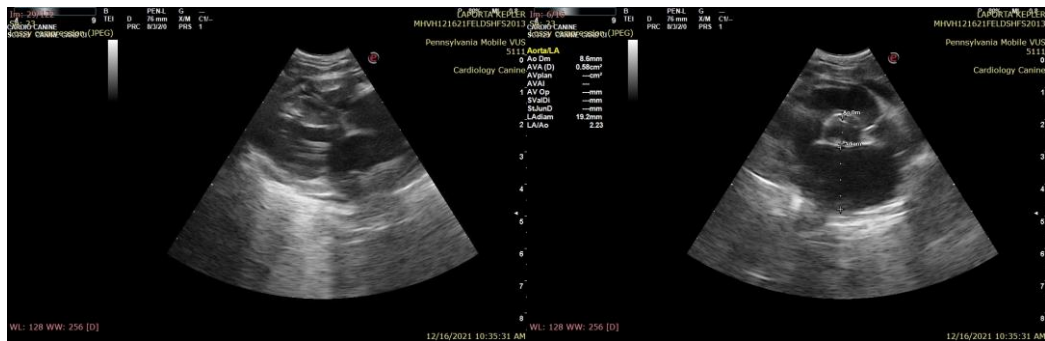
Maple Hills VH

REFERRING VET

Dr. Banzhof

DATE

12.16.2021



The information and recommendations provided are based on the images presented by the referring veterinarian. No evaluation can be communicated regarding pathology that was not visible in the image/video clips provided.

Thank you for this referral. If the clinical or image interpretation does not parallel your findings or if I can be of any further assistance please contact me.

Keith Blass, DVM, MS, DACVIM (Cardiology)
KeithBlass@gmail.com
631-804-5754